

Comparative Diagnostic Performances of Auscultation, Chest Radiography, and Lung Ultrasonography in Acute Respiratory Distress Syndrome

Daniel Lichtenstein, M.D.,* Ivan Goldstein, M.D.,† Eric Mourgeon, M.D.,† Philippe Cluzel, M.D., Ph.D.,‡ Philippe Grenier, M.D.,§ Jean-Jacques Rouby, M.D., Ph.D.||

Background: Lung auscultation and bedside chest radiography are routinely used to assess the respiratory condition of ventilated patients with acute respiratory distress syndrome (ARDS). Clinical experience suggests that the diagnostic accuracy of these procedures is poor.

Methods: This prospective study of 32 patients with ARDS and 10 healthy volunteers was performed to compare the diagnostic accuracy of auscultation, bedside chest radiography, and lung ultrasonography with that of thoracic computed tomography. Three pathologic entities were evaluated in 384 lung regions (12 per patient): pleural effusion, alveolar consolidation, and alveolar-interstitial syndrome.

Results: Auscultation had a diagnostic accuracy of 61% for pleural effusion, 36% for alveolar consolidation, and 55% for alveolar-interstitial syndrome. Bedside chest radiography had a diagnostic accuracy of 47% for pleural effusion, 75% for alveolar consolidation, and 72% for alveolar-interstitial syndrome. Lung ultrasonography had a diagnostic accuracy of 93% for pleural effusion, 97% for alveolar consolidation, and 95% for alveolar-interstitial syndrome. Lung ultrasonography, in contrast to auscultation and chest radiography, could quantify the extent of lung injury. Interobserver agreement for the ultrasound findings as assessed by the κ statistic was satisfactory: 0.74, 0.77, and 0.73 for detection of alveolar-interstitial syndrome, alveolar consolidation, and pleural effusion, respectively.

Conclusions: At the bedside, lung ultrasonography is highly sensitive, specific, and reproducible for diagnosing the main lung pathologic entities in patients with ARDS and can be considered an attractive alternative to bedside chest radiography and thoracic computed tomography.

AT the bedside, accurate evaluation of lung pathologic entities and pulmonary aeration in critically ill patients ventilated for acute respiratory distress syndrome (ARDS) remain problematic. Auscultation, which is the first step of the clinical evaluation, can be markedly altered by the intrathoracic transmission of sounds issued from the mechanical ventilator. Technical limitations reduce the quality of bedside chest radiography, which, nevertheless, remains the daily reference for lung imaging. These limitations include movements of the chest wall, patient rotation, supine position with the x-ray film cassette placed posterior to the thorax, and an x-ray beam originating anteriorly at a shorter distance than recommended and not tangentially to the apex of the hemidiaphragm. All of these various factors contribute to poor-quality x-ray films and mistaken assessment of pleural effusion, alveolar consolidation, interstitial markings, mediastinum, and cardiac dimensions. Even with careful control of exposure factors, radiographic images remain suboptimal in more than one third of cases¹⁻⁵ and are poorly correlated to lung computed tomographic images.⁶ Although it is generally believed that ultrasonography has limited applications in lung diseases, its use is extending in intensive care units.^{4,7-13}

The aim of this prospective study was to assess whether lung ultrasonography could be an alternative to bedside chest radiography for assessing the presence and extent of alveolar consolidation, alveolar-interstitial syndrome, and pleural effusion in ventilated patients with ARDS. Auscultation, bedside chest radiography, and lung ultrasonography were compared with thoracic computed tomography (CT).

Materials and Methods

Patients

Thirty-two consecutive patients admitted to the Surgical Intensive Care Unit of Pitié-Salpêtrière Hospital for treatment of ARDS were prospectively included in the study. ARDS was defined according to the American-European Consensus Conference on ARDS.¹⁴ All patients

This article is accompanied by an Editorial View. Please see: Hubmayr RD: The times are a-changin': Should we hang up the stethoscope? ANESTHESIOLOGY 2004; 100:1-2.

Additional material related to this article can be found on the ANESTHESIOLOGY Web site. Go to the following address, click on Enhancement Index, and then scroll down to find the appropriate article and link. <http://www.anesthesiology.org>. Supplementary material can also be accessed on the Web by clicking on the "ArticlePlus" link either in the Table of Contents or at the top of the Abstract or HTML version of the article.

* Assistant, Critical Care. Current position: Réanimation Médicale, Hôpital Ambroise Paré, Boulogne, France. † Chef de Clinique, Surgical Intensive Care Unit, ‡ Professor of Radiology, § Professor of Radiology, Chairman, Department of Radiology, || Professor of Anesthesiology and Critical Care, Medical Director, Surgical Intensive Care Unit.

Received from Réanimation Chirurgicale Pierre Viars, Department of Anesthesiology and Department of Radiology, Hôpital de la Pitié-Salpêtrière, Université Pierre et Marie Curie, Paris VI, France. Submitted for publication August 19, 2002. Accepted for publication July 30, 2003. Supported by a grant from Association pour la Recherche Clinique et Expérimentale en Anesthésie-Réanimation, Paris, France.

Address reprint requests to Professor Rouby: Réanimation Chirurgicale Pierre Viars, Department of Anesthesiology, Pitié-Salpêtrière Hospital, 47-83 Boulevard de l'Hôpital, 75013 Paris, France. Address electronic mail to: jjrouby.pitie@invivo.edu or jean-jacques.rouby@psl.ap-hop-paris.fr. Individual article reprints may be purchased through the Journal Web site, www.anesthesiology.org.

were monitored with Swan-Ganz and arterial catheters. Cardiorespiratory parameters, including static respiratory pressure-volume curves, were determined as previously described.^{6,15} Each patient with ARDS who was admitted during the study period was monitored *via* a specifically developed diagnostic and therapeutic strategy that included the following: assessment of lung morphology with thoracic CT, determination of the positive end-expiratory pressure (PEEP) according to the individual distribution of loss of aeration,¹⁶ administration of inhaled nitric oxide and/or intravenous almitrine, and maintenance of tidal volumes of less than 8 ml/kg. The Hospital ethics committee approved the therapeutic and investigational procedures, and written informed consent was obtained from the patient's next of kin. Partial results concerning the CT data have been previously reported in three studies.^{6,17,18}

Auscultation, Chest Radiography, Lung Ultrasonography, and Thoracic CT

Auscultation. Auscultation was performed by the same investigator (J.J.R.) immediately before transportation to the CT scanner. Twelve lung regions were systematically examined: the upper and lower parts of the anterior, lateral, and posterior regions of the left and right chest walls with the patient in the supine position. Auscultation was performed during tidal ventilation using the ventilatory setting selected according to the optimized therapeutic strategy.

Each auscultation was classified into categories corresponding to definitions proposed by Loudon and Murphy¹⁹ and using the terminology recommended by the American Thoracic Society.²⁰ Normal auscultation was defined as the presence of normal vesicular sounds in each region examined. Auscultation suggestive of pleural effusion was defined as the abolition of normal vesicular sounds in one or several regions. Auscultation suggestive of alveolar consolidation was defined as the presence in one or several regions of bronchial breath sounds predominating during the inspiratory phase and characterized by a hollow or tubular timbre. Auscultation suggestive of alveolar-interstitial syndrome was defined as the presence in one or several regions of fine crackles during the inspiratory phase.

The extent of lung injury was assessed as the number of regions where auscultation was suggestive of alveolar consolidation and/or alveolar-interstitial syndrome.

Chest Radiography. Using the same ventilatory settings and with the patient in the supine position, anterior portable radiographs were obtained before CT by using an AMX4 (General Electric, Kawasaki, Japan) with high voltage (120–130 kV) that was read by an independent radiologist unaware of the ultrasonographic and CT patterns. Exposure time, focus-film distance, and degree of exposure were standardized for each patient to obtain the best radiographic quality. Lung parenchyma was

divided into 12 regions by a cephalocaudal mid-axillary line and a transversal hilar line. Upper lung regions were defined as lung regions delineated by the apex, mid-axillary line, mediastinal line, and hilar line. Upper and lower lateral lung regions were defined as lung regions delineated by the external limit of the chest wall, mid-axillary line, and apex (upper) or diaphragm (lower). Upper and lower posterior lung regions were defined as lung regions with radiologic signs erasing the mediastinum border ("silhouette sign") and delineated by the mediastinum, mid-axillary line, hilar line, and apex (upper) or diaphragm (lower).

Pleural effusion, alveolar consolidation, and alveolar-interstitial syndrome were defined according to criteria established for patients with ARDS^{5,21} and using the terminology recommended by the Nomenclature Committee of the Fleischner Society.²² Pleural effusion was defined as the presence in the lower lung regions of a homogeneous opacity in which bronchovascular markings were visible with a blunting of the diaphragmatic cupula and/or a thickening of the pleural surface laterally. A grayish opacity throughout a hemithorax with lung markings still visible was also considered as indicative of pleural effusion. Alveolar consolidation was defined as the presence in lower lung regions of a homogeneous opacity characterized by the effacement of blood vessel shadows and the presence of air bronchograms. Alveolar-interstitial syndrome was defined as the presence in one or several lung regions of one or more of the following radiologic entities: septal lines representing thickened interlobular septa, reticulonodular pattern, and patchy and poorly defined air space opacifications with air bronchograms and a peripheral distribution.

The extent of lung injury was assessed as the number of lung regions with radiologic signs suggestive of alveolar consolidation or alveolar-interstitial syndrome.

Lung Ultrasonography. Lung ultrasonography was performed immediately before CT, with the same ventilatory parameters, by a single operator (D.L.) with a Hitachi-405 (Hitachi Medical Corporation, Tokyo, Japan) and a microconvex 5 MHz, 9-cm-long probe. The 12 lung regions of the chest wall that were explored by auscultation were also explored by lung ultrasonography. For a given region of interest, multiple sites were analyzed. Additional information regarding this procedure is available on the ANESTHESIOLOGY Web site at <http://www.anesthesiology.org>. If an ultrasound abnormality was detected in a single site or several sites, then the region of interest was considered characterized by this abnormality. A given region of interest could be characterized by several ultrasound abnormalities. Anterolateral parts of the chest wall were examined with the patient in the supine position, whereas posterior parts were examined with the patient in the lateral position. Lung ultrasound

examinations were also performed for a control group of 10 healthy subjects to determine a normal ultrasound lung pattern.

Lung ultrasonograms were contemporaneously classified into four categories according to previously described criteria.^{7-9,12,23-26} The pleural line was defined as a horizontal hyperechoic line visible 0.5 cm below the rib line. Horizontal lines, arising from and parallel to the pleural line, were called *A lines*; vertical lines, arising from and perpendicular to the pleural line, were called *B lines* or *comet tails* if they reached the edge of the screen; and three or more comet tails visible in a frozen image were called *lung rockets*.²⁷ A normal pattern was determined with the healthy volunteers and was defined as the presence in every lung region of lung sliding with *A lines*.⁸ A single comet tail present in an anterior lung region, or multiple comet tails confined laterally to the tenth or eleventh intercostal space, were found for one third of the healthy volunteers and considered as normal.⁹ Pleural effusion was defined as a dependent collection limited by the diaphragm and the pleura²³⁻²⁵ (fig. 1) with an inspiratory movement of the visceral pleura from depth to superficialities¹² (fig. 1b). In the case of abundant effusion, the consolidated and atelectatic lung was visible floating in the pleural effusion. Alveolar consolidation was defined as the presence in one or several lung regions of tissular pattern 7 whose dimensions remained unchanged throughout the respiratory cycle. It contained frequently hyperechoic punctiform images representative of air bronchograms²⁶ (fig. 1b). Alveolar-interstitial syndrome was defined as the presence of more than two *B lines* in a given lung region. *B lines* 7 mm apart corresponded to thickened interlobular septa, and *B lines* 3 mm apart or less corresponded to ground-glass areas (figs. 1d and f). In an additional series of ventilated patients with acute lung injury, 288 lung regions defined as mentioned above were examined using lung ultrasonography by two of three investigators (I.G., Belaid Bouhemad, M.D., and/or J.J.R.) blinded to one another. Each of the 12 lung regions examined per patient was classified into one or several of the four categories defined above. Additional information regarding the lung ultrasound semiology is available on the ANESTHESIOLOGY Web site at <http://www.anesthesiology.org>.

The extent of lung injury was assessed as the number of lung regions where lung ultrasonography was suggestive of alveolar-interstitial syndrome or alveolar consolidation.

Thoracic CT. As previously described,¹⁸ each patient was transported to the radiology department by two physicians using appropriate cardiorespiratory monitoring. With the patient in the supine position, lung scanning was performed from the apex to the diaphragm using a Tomoscan SR 7000 (Philips, Eindhoven, The Netherlands). All images were observed and photographed at a window width of 1,600 HU and a level of

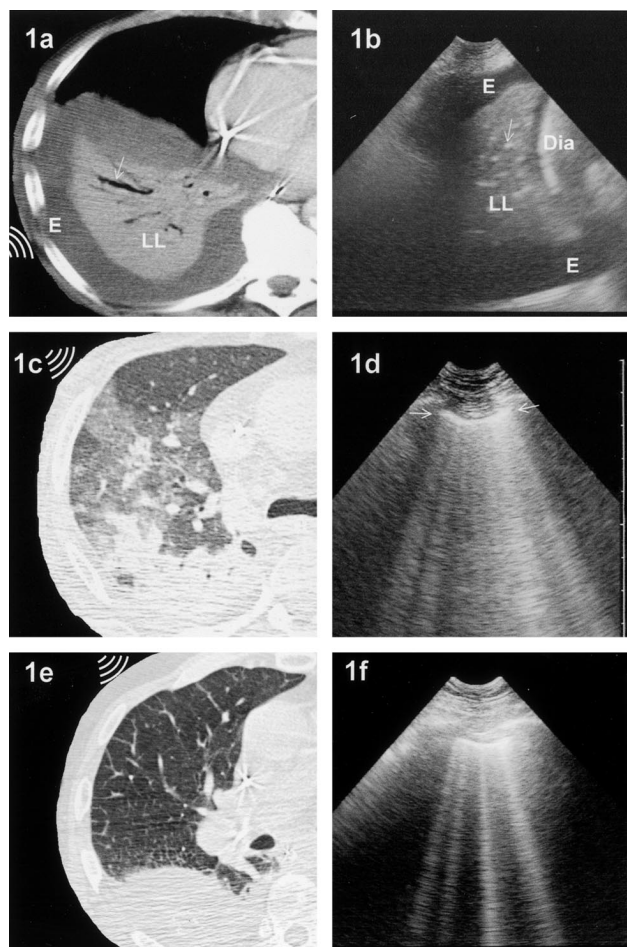


Fig. 1. Computed tomographic and lung ultrasound aspects, respectively, of pleural effusion, alveolar consolidation, and alveolar-interstitial syndrome. (a,b) Fluid collection (*E*) delimited by the diaphragm (*Dia*) and the parietal and visceral pleura surrounding a consolidated lower lobe (*LL*) containing hyperechoic punctiform structures (air bronchogram; arrows). (c,d) Long comet tail artifacts arising from the pleural line (i.e., *B lines*) and multiple lung rockets at a distance of 3 mm or less and representative of ground-glass areas (pleural line; arrows). (e,f) Multiple comet tail artifacts (four *B lines*) at a distance of 7 mm and representative of thickened interlobular septa. The pattern is reminiscent of a rocket at liftoff, hence the practical term *lung rockets*.

–600 Hounsfield units. The exposures were taken at 120 kV and 250 mA. The value of the pitch was 1. In each patient, 80 ml of contrast material was injected to differentiate pleural effusions from alveolar consolidation. Evaluation included thin and spiral CT sections obtained at end expiration, with a PEEP that had been selected by the physician in charge. The thin-section CT examination consisted of a series of 1.5-mm sections with 20-mm intersection spacing selected by means of a thoracic scout view during a 15-s period of apnea. For spiral CT, contiguous axial sections 10 mm thick were reconstructed from the volumetric data as previously described.²⁸ For eight patients, CT sections were recorded on an optical disk for computerized analysis of

lung volumes using validated software.²⁹ An independent radiologist (P.C.) was assigned to interpret the CT results. The 12 lung regions that were explored by auscultation, chest radiography, and lung ultrasonography were analyzed using CT: the right and left anterior, lateral, and posterior upper lung regions and the right and left anterior, lateral, and posterior lower lung regions were determined using the same anatomic landmarks (apex, mid-axillary line, external limit of the rib cage, mediastinum border, and diaphragm).

Pleural effusion, alveolar consolidation, and alveolar-interstitial syndrome were defined according to the recommendations of the Fleischner Society.³⁰ Pleural effusion was defined as a homogeneous and peripheral opacification free of any air bronchograms and characterized by a CT attenuation lower than the CT attenuation of adjacent alveolar consolidation (fig. 1a). Alveolar consolidation was defined as an attenuation obscuring margins of vessels and airways associated with an air bronchogram (fig. 1a). Alveolar-interstitial syndrome was defined as the presence of one or several of the following features: ground-glass opacities appearing as areas of hazy increased lung attenuation not associated with obscuration of underlying vessels, reticulation made of innumerable interlacing line shadows suggesting a mesh, and septal thickening appearing as abnormal widening of interlobular septa abutting the visceral pleural surface (fig. 1, c and e).

The extent of lung injury was defined as the percentage of lung volume either poorly or not aerated³¹ and quantitatively assessed in eight patients using specifically designed CT software (Lungview; Institut National des Télécommunications, Evry, France).²⁹

Statistical Analysis

All data are expressed as mean \pm SD. The accuracy of each method was represented as follows: sensitivity = (true positive/[true positive + false negative]); specificity = (true negative/[true negative + false positive]); and diagnostic accuracy = ((true positive + true negative)/[true positive + true negative + false positive + false negative]). The ability of auscultation, chest radiography, and lung ultrasonography to reflect the extent of lung injury was tested by means of Spearman rank correlation analysis between the number of lung regions demonstrating alveolar-interstitial syndrome and alveolar consolidation and the CT extension of poorly and nonaerated lung regions. Correlation between two methods was considered clinically relevant when the non-parametric correlation coefficient (ρ) was 0.65 or greater. The level of agreement among observers for the ultrasound findings was evaluated with the 288 additional lung regions examined and analyzed using the κ reliability test.³² κ values less than 0.40 indicate low agreement, values between 0.40 and 0.75 indicate medium agreement, and values greater than 0.75

indicate high agreement between the two raters. $P < 0.05$ was considered as the level of statistical significance.

Results

Patients

Thirty-two patients with ARDS were prospectively included in the study. The mean age of the patients was 58 ± 15 yr. The mean delay between the onset of ARDS and the study was 5.4 ± 4 days. Initial etiologies were major surgery ($n = 19$), multiple trauma ($n = 5$), and medical disease ($n = 8$). In 27 patients, ARDS was caused by a primary insult to the lung (bronchopneumonia, 18; pulmonary contusion, 4; aspiration pneumonia, 4; and fat embolism, 1), and in five patients, it was caused by a secondary insult to the lung (septic shock, 3; and lung injury complicating cardiopulmonary bypass, 2). At study inclusion, the mean lung injury severity score³³ was 2.6 ± 0.8 , and the mean ARDS severity score⁶ was 11 ± 6 . Patients had a mean P_{aO_2} of 166 ± 80 mmHg (fraction of inspired oxygen, 1; no PEEP), a mean pulmonary shunt of $43 \pm 13\%$, a mean pulmonary arterial pressure of 29 ± 7 mmHg, a mean pulmonary vascular resistance index of 348 ± 20 dyn \cdot s⁻¹ \cdot cm⁻⁵ \cdot m⁻², a mean pulmonary wedge pressure of 13 ± 3 mmHg, and a mean static respiratory compliance of 53 ± 20 ml/cm H₂O. Using a mean tidal volume of 8 ± 2 ml/kg, the mean P_{aCO_2} was 43 ± 9 mmHg. The mortality rate was 42%. After diagnostic and therapeutic strategy optimization, a PEEP of 12 ± 5 cm H₂O was applied with a mean tidal volume of 6.7 ± 1 ml/kg.

Comparative Diagnostic Accuracy

According to CT criteria, of the 384 lung regions examined, 26% had pleural effusion, 31% had alveolar consolidation, and 48% had alveolar-interstitial syndrome. As shown in table 1, auscultation and bedside chest radiography were less accurate than lung ultrasonography for diagnosing pleural effusion, alveolar consolidation, and alveolar-interstitial syndrome in the 384 lung regions examined.

Bedside chest radiography was a poor predictor of the extent of lung injury compared with lung ultrasonography. The percentage of lung injury measured using CT (y ; the percentage of overall lung volume either poorly or not aerated) significantly correlated with the extent of lung injury measured by lung ultrasonography (x ; the percentage of lung regions with an ultrasound pattern suggestive of alveolar-interstitial syndrome or alveolar consolidation): $y = 1.3x + 73$ ($\rho = 0.76$; $P = 0.003$). When alveolar consolidation and alveolar-interstitial syndrome were assessed using bedside frontal chest radiography, the correlation did not reach statistical significance ($y = 1.02x + 32$; $r = 0.45$; $P = 0.3$). For the 32

Table 1. Sensitivity and Specificity of Auscultation, Chest Radiography, and Lung Ultrasonography for Diagnosing Pleural Effusion, Alveolar Consolidation, and Alveolar-Interstitial Syndrome in 384 Lung Regions in 32 Critically Ill Patients with ARDS

	Auscultation, %	Chest Radiography, %	Lung Ultrasonography, %
Pleural effusion			
Sensitivity	42	39	92
Specificity	90	85	93
Diagnostic accuracy	61	47	93
Alveolar consolidation			
Sensitivity	8	68	93
Specificity	100	95	100
Diagnostic accuracy	36	75	97
Alveolar-interstitial syndrome			
Sensitivity	34	60	98
Specificity	90	100	88
Diagnostic accuracy	55	72	95

ARDS = acute respiratory distress syndrome.

patients, 384 lung regions were analyzed by auscultation, lung ultrasonography, and CT. Only 52% of the lung regions analyzed by auscultation were concordant with the corresponding CT lung regions, whereas 83% of the lung regions analyzed by lung ultrasonography were concordant with the corresponding CT lung regions.

Interobserver Variability

For the 288 lung regions analyzed by two of three investigators in the additional series of ARDS patients, κ values for assessing normal lung ultrasonography pattern, alveolar-interstitial syndrome, alveolar consolidation, and pleural effusion were 0.69, 0.74, 0.77, and 0.75, respectively.

Discussion

For patients with ARDS, lung ultrasonography is better than auscultation and bedside chest radiography for diagnosing pleural effusion, alveolar consolidation, and alveolar-interstitial syndrome and for assessing the extent of lung injury.

Normally, ultrasounds are not transmitted through anatomic structures filled with gas, and the lung parenchyma is not visible beyond the pleura. In injured lung, which is characterized by a marked increase in tissue extending to the lung periphery,¹⁸ artifacts resulting from the gas-tissue interface are detected by lung ultrasonography as comet tails. Correlations with CT have demonstrated that lung rockets (multiple comet tails at 7-mm intervals) correspond to thickened alveolar septa,

whereas lung rockets at 3-mm or shorter intervals correspond to ground-glass attenuation areas.^{9,10,27} When the loss of aeration is massive and results in an alveolar consolidation adjacent to the pleura, the lung becomes visible as a tissular structure with hyperechoic artifacts resulting from air bronchograms.⁷ It has been shown that lung ultrasonography is highly sensitive and specific for detecting pleural effusion,^{12,23-25} and it can help thoracentesis.¹² Recently, Tsubo *et al.*¹³ demonstrated that PEEP-induced re-aeration of a hyperdense left lower lobe can be assessed using transesophageal ultrasonography. When a PEEP of 15 cm H₂O was used for patients with ARDS and nonaerated lower lobes, these investigators found that ultrasonic densities "disappeared." Figure 6 in their article shows that it is highly likely that at PEEP of 15 cm H₂O a tissular pattern suggestive of lung consolidation was replaced by multiple comet tails. In other words, a gas-tissue interface was observed after PEEP, indicative of partial re-aeration of the left lower lobe. Complete lung re-aeration would have resulted in the appearance of horizontal A lines parallel to the pleural line. From these results and our clinical experience, lung ultrasonography could be a very valuable tool to assess at the bedside lung recruitment resulting from PEEP. Further studies are required to confirm this possibility.

Lung ultrasonography is also sensitive and specific for diagnosing pneumothorax,⁸⁻¹⁰ maxillary sinusitis,³⁴ and many other disorders in critically ill patients.^{35,36} Compared with CT, which provides direct visualization of lung morphology, lung ultrasonography shows artifacts resulting from lung injury and is therefore less demonstrative. However, it has the major advantages of avoiding radiation exposure as well as transportation outside the intensive care unit and is less costly and easily repeatable. In addition, it allows the accurate diagnosis of pleural effusion, alveolar consolidation, and alveolar-interstitial syndrome not only in ARDS but also in many other types of lung injury.^{7,24,25,27} CT requires transportation of the patient to the radiology department and trained physicians familiar with mechanical ventilation and complex cardiovascular monitoring. For improving the quality of the images, intravenous injection of contrast material is helpful but may be detrimental to the injured lung.³⁷ The radiation dose delivered to the patient with CT examination of the entire chest using 10-mm collimation remains high, equivalent to undergoing chest radiography 20-30 times.³⁸ The cost of one CT examination is approximately \$690. In addition, CT should not be frequently repeated and is not available everywhere for critically ill patients.

As recommended by the American College of Radiology,³⁹ we perform daily chest radiography for ventilated patients who do not fulfill the criteria of ARDS for detecting pleural effusion, alveolar consolidation, and alveolar-interstitial syndrome. Because additional chest

radiographs are also obtained for assessing the adequate position of monitoring and therapeutic devices, a mean of 1.2 chest radiographs per patient per day is obtained in our unit. Because we admit 240 patients a year with a mean duration of mechanical ventilation of 15 days, approximately 4,300 chest radiographs are taken each year, representing a cost of \$222,271. If the systematic use of lung ultrasonography in the intensive care unit resulted in a 50% decrease in the number of radiographs and according to the price of a single sonogram (\approx \$51,460), \$59,673 would be saved the first year and \$111,172 for the following years.

Lung ultrasonography has some shortcomings. For obese patients and multiple trauma patients with subcutaneous emphysema, visualization of lung parenchyma might be difficult. Adequate interpretation of lung ultrasonographic findings requires special training and some experience. However, because ultrasound abnormalities are well defined and easy to recognize, operator dependence is minimal, as demonstrated by the high interobserver agreement found in the current study. The three physicians involved in the evaluation of interobserver reproducibility had 2 months of training (conducted by D.L.). Because the same probe serves multiple patients, it can be the vector of, or disseminate resistant pathogens in, the intensive care unit and imposes special decontamination procedures.⁴⁰ Last, but not least, lung ultrasonography allows the detection of tube malposition, and bedside chest radiography remains the reference for checking adequate position of indwelling catheters. Finally, these limitations should be balanced against the benefits of lung ultrasonography, which has a direct diagnostic and therapeutic impact for more than two thirds of critically ill patients.⁴

In conclusion, the routine use of lung ultrasonography for critically ill patients with ARDS could reduce the indications of bedside chest radiography and thoracic CT. As a result, the cost of patient care in the intensive care unit should decrease, and at the same time, more accurate information should become available on the presence and extent of pleural effusion, alveolar consolidation, and alveolar-interstitial syndrome. Lung ultrasonography may open a new era of respiratory monitoring in the intensive care unit.

The authors thank Véronique Connan (Secretary) and Jacqueline Gardillou (Secretary, Department of Anesthesiology, Hôpital de la Pitié-Salpêtrière) for their excellent secretarial assistance, and Belaid Bouhemad, M.D. (Department of Anesthesiology, Hôpital de la Pitié-Salpêtrière), for participating in the assessment of lung ultrasound reproducibility.

References

- Henschke CI, Pasternack GS, Schroeder S, Hart KK, Herman PG: Bedside chest radiography: Diagnostic efficacy. *Radiology* 1983; 149:23-6
- Janower ML, Jennas-Nocera Z, Mukai J: Utility and efficacy of portable chest radiographs. *AJR Am J Roentgenol* 1984; 142:265-7
- Greenbaum DM, Marschall KE: The value of routine daily chest x-rays in

intubated patients in the medical intensive care unit. *Crit Care Med* 1982; 10:29-30

4. Yu CJ, Yang PC, Chang DB, Luh KT: Diagnostic and therapeutic use of chest sonography: Value in critically ill patients. *AJR Am J Roentgenol* 1992; 159:695-701

5. Wiener MD, Garay SM, Leitman BS, Wiener DN, Ravin CE: Imaging of the intensive care unit patient. *Clin Chest Med* 1991; 12:169-98

6. Rouby JJ, Puybasset L, Cluzel P, Richecoeur J, Lu Q, Grenier P, CT Scan ARDS Study Group: Regional distribution of gas and tissue in acute respiratory distress syndrome: II. Physiological correlations and definition of an ARDS severity score. *Intensive Care Med* 2000; 26:1046-56

7. Yang PC, Luh KT, Chang DB, Yu CJ, Kuo SH, Wu HD: Ultrasonographic evaluation of pulmonary consolidation. *Am Rev Respir Dis* 1992; 146:757-62

8. Lichtenstein DA, Menu Y: A bedside ultrasound sign ruling out pneumothorax in the critically ill: Lung sliding. *Chest* 1995; 108:1345-8

9. Lichtenstein D, Meziere G, Biderman P, Gepner A, Barre O: The comet-tail artifact: An ultrasound sign of alveolar-interstitial syndrome. *Am J Respir Crit Care Med* 1997; 156:1640-6

10. Lichtenstein D, Meziere G, Biderman P, Gepner A: The comet-tail artifact: An ultrasound sign ruling out pneumothorax. *Intensive Care Med* 1999; 25:383-8

11. Lichtenstein D, Meziere G, Biderman P, Gepner A: The lung point: An ultrasound sign specific to pneumothorax. *Intensive Care Med* 2000; 26:1431-40

12. Lichtenstein D, Hulot JS, Rabiller A, Tostivint I, Meziere G: Feasibility of ultrasound-aided thoracocentesis in mechanically ventilated patients. *Intensive Care Med* 1999; 25:955-8

13. Tsubo T, Sakai I, Suzuki A, Okawa H, Ishihara H, Matsuki A: Density detection in dependent left lung region using transesophageal echocardiography. *ANESTHESIOLOGY* 2001; 94:793-8

14. Bernard GR, Artigas A, Brigham KL, Carlet J, Falke K, Hudson L, Lamy M, Legall JR, Morris A, Spragg R: The American-European Consensus Conference on ARDS: Definitions, mechanisms, relevant outcomes, and clinical trial coordination. *Am J Respir Crit Care Med* 1994; 149:818-24

15. Lu Q, Vieira SR, Richecoeur J, Puybasset L, Kalfon P, Coriat P, Rouby JJ: A simple automated method for measuring pressure-volume curves during mechanical ventilation. *Am J Respir Crit Care Med* 1999; 159:275-82

16. Rouby JJ, Lu Q, Goldstein I: Selecting the right positive end-expiratory pressure in patients with acute respiratory distress syndrome. *Am J Respir Crit Care Med* 2002; 165:1182-6

17. Puybasset L, Muller JC, Cluzel P, Coriat P, Rouby JJ, CT Scan ARDS Study Group: Regional distribution of gas and tissue in acute respiratory distress syndrome: III. Consequences on the effects of positive end-expiratory pressure. *Intensive Care Med* 2000; 26:1215-27

18. Puybasset L, Cluzel P, Gusman P, Grenier P, Preteux F, Rouby JJ, CT Scan ARDS Study Group: Regional distribution of gas and tissue in acute respiratory distress syndrome: I. Consequences on lung morphology. *Intensive Care Med* 2000; 26:857-69

19. Loudon R, Murphy RLH: Lung sounds. *Am Rev Respir Dis* 1984; 130:663-73

20. American Thoracic Society Ad Hoc Committee on Pulmonary Nomenclature: Updated nomenclature for membership reaction. *ATS News Fall* 1977; 3:5-6

21. Wheeler AP, Carroll FE, Bernard GR: Radiographic issues in adult respiratory distress syndrome. *New Horiz* 1993; 1:471-7

22. Tuddenham WJ: Glossary of terms for thoracic radiology: Recommendations of the Nomenclature Committee of the Fleischner Society. *AJR Am J Roentgenol* 1984; 143:509-17

23. Joyner CR Jr, Herman RJ, Reid JM: Reflected ultrasound in the detection and localization of pleural effusion. *JAMA* 1967; 200:399-402

24. Doust BD, Baum JK, Maklad NF, Doust VL: Ultrasonic evaluation of pleural opacities. *Radiology* 1975; 114:135-40

25. Sandweiss DA, Hanson JC, Gosink BB, Moser KM: Ultrasound in diagnosis, localization, and treatment of loculated pleural empyema. *Ann Intern Med* 1975; 82:50-3

26. Weinberg B, Diakoumakis EE, Kass EG, Seife B, Zvi ZB: The air bronchogram: Sonographic demonstration. *AJR Am J Roentgenol* 1986; 147:593-5

27. Lichtenstein D, Meziere G: A lung ultrasound sign allowing bedside distinction between pulmonary edema and COPD: The comet-tail artifact. *Intensive Care Med* 1998; 24:1331-4

28. Lu Q, Malbouisson M, Mourgeon E, Goldstein I, Coriat P, Rouby JJ: Assessment of PEEP-induced reopening of collapsed lung regions in acute lung injury: Are one or three CT sections representative of the entire lung? *Intensive Care Med* 2001; 27:1504-10

29. Malbouisson LM, Preteux F, Puybasset L, Grenier P, Coriat P, Rouby JJ: Validation of a software designed for computed tomographic (CT) measurement of lung water. *Intensive Care Med* 2001; 27:602-8

30. Austin JHM, Muller N, Friedman PJ, Hansell DM, Nalidich DP, Remy-Jardin M, Webb WR, Zerhouni EA: Glossary of terms for CT of the lungs: Recommendations of the Nomenclature Committee of the Fleischner Society. *Radiology* 1996; 200:327-31

31. Rouby JJ, Puybasset L, Nieszkowska A, Lu Q: Acute respiratory distress syndrome: Lessons from computed tomography of the whole lung. *Crit Care Med* 2003; 31:S285-95

32. Fleiss JL: The measurement of inter-rater agreement, *Statistical Methods for Rates*. Edited by Fleiss JL. New York, Wiley, 1981, pp 212-25
33. Murray JF, Mathay JM, Luce JM, Flick MR: An expanded definition of the adult respiratory distress syndrome. *Am Rev Respir Dis* 1988; 138:720-3
34. Lichtenstein D, Biderman P, Meziere G, Gepner A: The "sinusogram": A real-time ultrasound sign of maxillary sinusitis. *Intensive Care Med* 1998; 24: 1057-61
35. Lichtenstein D, Axler O: Intensive use of general ultrasound in the intensive care unit: Prospective study of 150 consecutive patients. *Intensive Care Med* 1993; 19:353-5
36. Lichtenstein D: *L'échographie générale en réanimation*, 1st edition. Paris, Berlin, New York, Springer-Verlag, 1992, pp 139-41
37. Bouhemad B, Richecoeur J, Lu Q, Malbouisson LM, Cluzel P, Rouby JJ: Effects of contrast material on computed tomographic measurements of lung volumes in patients with acute lung injury. *Crit Care* 2003; 7:63-71
38. Naidich DP, Pizzarello D, Garay SM, Müller NL: Is thoracic CT performed often enough? *Chest* 1994; 106:331-2
39. Henschke CI, Yankelevitz DF, Wand A, Davis SD, Shiao M: Accuracy and efficacy of chest radiography in the intensive care unit. *Radiol Clin North Am* 1996; 34:21-31
40. Muradali D, Gold WL, Phillips A, Wilson R: Can ultrasound probes and coupling gel be a source of nosocomial infection in patients undergoing sonography? An in vivo and in vitro study. *AJR Am J Roentgenol* 1995; 164:1521-4